

# The position of maxillary canine impactions and the influenced factors to adjacent root resorption in the Korean population

Yoojun Kim, Hong-Keun Hyun and Ki-Taeg Jang

Department of Pediatric Dentistry and Dental Research Institute, School of Dentistry, Seoul National University, Seoul, Korea

Correspondence to: Dr Ki-Taeg Jang, Department of Pediatric Dentistry and Dental Research Institute, School of Dentistry, Seoul National University, 275-1 Yongon-dong, Chongno-gu, Seoul 110-768, Korea. E-mail: jangkt@snu.ac.kr

**SUMMARY** The purpose of this study was to evaluate the position and aspects of maxillary canine impactions in the Korean population and investigate its comparison with the previous reports, while aiding in the establishment of diagnosis and treatment planning by revealing the influential factors of root resorption associated with such impactions. The subjects of this study consisted of 186 teeth from 148 patients, who had visited Seoul National University Dental Hospital due to impacted canines and had taken computerized tomographic images and panorama radiographic images. As a result, maxillary canine impaction in the Korean population occurred 1.5 times more often in females (F:M = 89:59) than males. Regarding the position of impaction, there were three times more buccal impactions (B:P = 140:46) than palatal impactions. The occurrence of root resorption was as high as 49.5 per cent. In evaluating the influential factors affecting adjacent root resorption, the significance of the impacted angulation was insufficient ( $P = 0.652$ ). However, the buccopalatal position ( $P < 0.0001$ ) and mesiodistal placement ( $P = 0.006, 0.037$ ) of the impacted tooth were determined to be significant factors. Therefore, the adjacent root resorption caused by impacted maxillary canines can be stated to exhibit a greater amount of resorption as the positional proximity of the canine crown and lateral incisor root increases.

## Introduction

In pathological terms, impacted teeth can be defined as a state where a tooth remains embedded in the oral mucosa or bone past its normal eruption period. However, the clinical definition of impacted teeth can be broadened to include teeth that are predicted to undergo abnormal eruption, even before its normal eruption period, due to position of tooth germ, tooth shape, direction of eruption, and available space (Andreasen *et al.*, 1997; Becker, 2007).

Eruption disturbance is commonly found during the stages of transition from primary dentition to mixed dentition, through to permanent dentition. Eruption disturbances of the maxillary canine often result in its impaction because of its position and eruption sequence. The prevalence of maxillary canine impaction is approximately 1–5 per cent (Thilander and Myrberg, 1973; Ericson and Kurol, 1986; Mevlut *et al.*, 2010; Rui *et al.*, 2010), which occurs more commonly than other teeth, except for third molars (Andreasen *et al.*, 1997; Kung and Hwang, 1993). However, the exact aetiology of impacted maxillary canines is still unknown (Alqerban *et al.*, 2009).

It is known that the impaction of maxillary canines occurs twice as much in females than males (Dachi and Howell, 1961; Becker *et al.*, 1981; Ericson and Kurol, 1986). In general, it has been reported that palatal impactions occur

more frequently than buccal impactions with a ratio from 2:1 (Fournier *et al.*, 1982) to 6:1 (Stellzig *et al.*, 1994). However, it was mentioned that there seems to be more buccal impactions in the Asian population (Oliver *et al.*, 1989). This finding refers to the possibility of a greater occurrence of buccal maxillary canine impactions in Asians. However, there is still not enough research to prove that this statement is true.

Not only do maxillary canine impactions cause aesthetic problems, like tipping of adjacent teeth and midline deviations, but they can also transpose, root resorb, and develop cystic masses on adjacent teeth and also arising infection and pain (Becker *et al.*, 1981; Jacoby, 1983). Among these problems, the most common complication is root resorption of adjacent teeth (Jacoby, 1983; Ericson and Kurol, 2000).

Ericson and Kurol (1987) stated from their research that 12.5 per cent of the ectopic eruptions of maxillary canines cause adjacent root resorption. Afterwards, they reported a greater rate of 48 per cent of adjacent teeth undergoing root resorption as a result of studying the rate of root resorption from maxillary canine impactions using computerized tomographic (CT) images in 2002 (Ericson and Kurol, 2000). This demonstrates that CT images can be used to clearly evaluate the relationship between impacted teeth and their adjacent teeth.

The purpose of this study was to investigate and evaluate the position and aspects of impacted maxillary canines in the Korean population and report whether or not the results have any relevance to previous studies of Caucasians. In addition, the relationship between the characteristics of impacted maxillary canines and adjacent root resorption was analysed to reveal factors directly involved in root resorption.

## Materials and methods

### *Experimental materials*

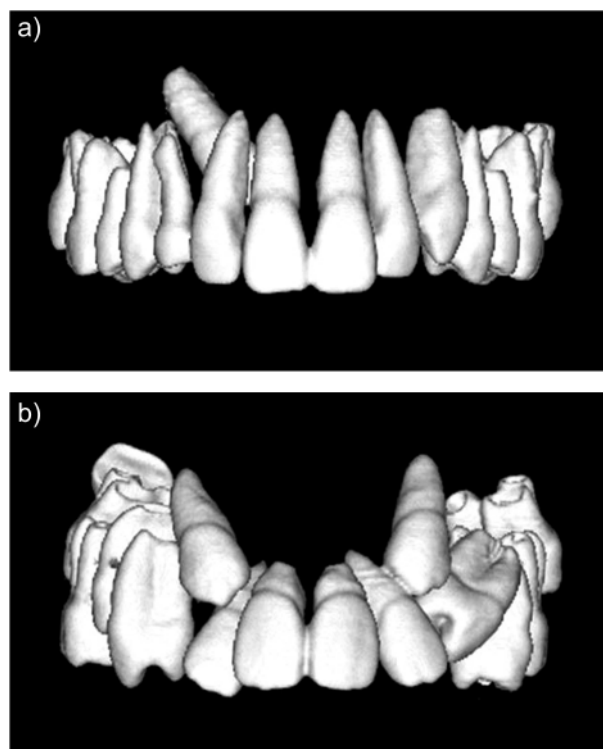
The subjects of this study were all the patients who had visited Seoul National University Dental Hospital between the years of 2005 and 2009, due to impacted canines, and had CT images and panorama radiographic images taken. Patients with a history of systemic disease, possessing many impacted teeth and, thus, possibly implying the presence of a syndrome, or exhibiting cases with a definite obstacle, like odontomas or supernumerary teeth, were exempted from this study.

One hundred and seventy-two patients with a total of 217 teeth satisfied the above conditions. However, the positioning of impacted teeth and adjacent root resorption evaluations of this study was based on the maxillary lateral incisor. Therefore, 30 subject teeth (maxillary canines), which were directed towards the first premolar and one subject tooth whose impacted position relative to the lateral incisor root was difficult to define displayed indefinite characteristics. Due to these findings, the above 31 teeth were exempted from the study. As a result, 148 patients satisfied the selection criteria, and, of those patients, 38 had bilateral impaction (where both the left and the right canines were impacted, considered as two separate canine impactions), making the total number of teeth 186. This study was approved by the Institutional Review Board at the School of Dentistry of Seoul National University (IRB No. S-D20100004).

### *Radiographic assessment*

The Orthopantomograph OP100 (Instrumentarium Corp., Helsinki, Finland) was used for panoramic radiographs and CT images were taken using SOMATOM Sensation 10 (Siemens AG, Erlangen, Germany), with a slice thickness of 0.75mm. The determination of the buccopalatal positioning of the impacted canines was based on the root of the adjacent lateral incisor. In other words, the focus was on whether the tip of the canine crown was on the buccal or the palatal side of the lateral incisor root (Figure 1).

For the mesiodistal evaluation of the impacted canines, two standard lines were depicted on the panoramic radiographic images by applying a modification of the method suggested by Lindauer *et al.* (1992). One line was constructed by joining the point at the most distal height of

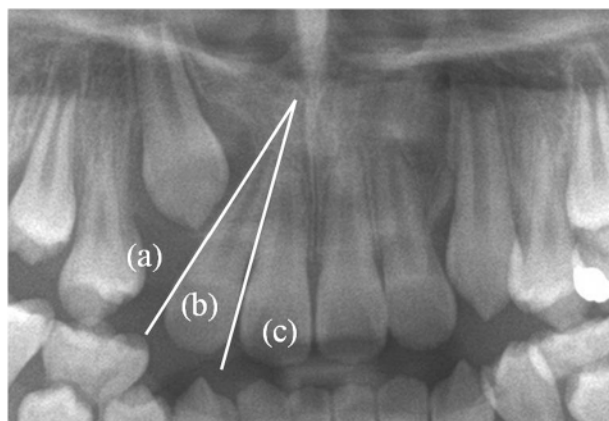


**Figure 1** An example of buccal and palatal impaction of the maxillary canine in three-dimensional computerized tomographic images.

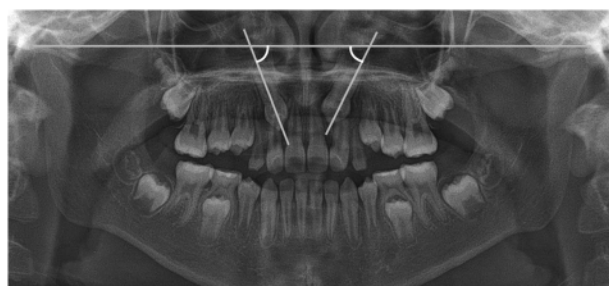
contour on the crown and root of the lateral incisor, while the other line was constructed by joining the point at the most mesial height of contour on the crown and root of the lateral incisor (Figure 2). Sector I represents the area in which the tip of the impacted canine lies distal to the first line, displaying no overlap with the lateral incisor in the panoramic radiographic image. Sector II is mesial to sector I, but distal to the second line, where the canine tip appears overlapped but did not pass through the lateral incisor. Sector III represents the whole area mesial to sector II, where the canine tip appears to have completely passed through the lateral incisor.

The impacted angulation of the maxillary canine was also evaluated using the panoramic radiographic image. For this study, the bicondylar line presented by Warford *et al.* (2003) was used as the standard, where the bicondylar line was created by joining the most superior point of each of the two condyles. Therefore, the definition of impacted angulation is the inner angle formed by the bicondylar line and the axial line (line connecting the tip of the crown and the apex) of the canine (Figure 3).

For the evaluation of the degree of adjacent root resorption, this study selected three categories. Adjacent roots unaffected by the impacted canine were referred to as 'no resorption (N)', roots displaying discontinuity of the lamina dura or root resorption as 'root resorption (R)', and roots with severe root resorption and pulpal invasion were



**Figure 2** Two standard lines for the mesiodistal placement evaluation of the impacted canine. The area in which the impacted canine appears distal to the lateral incisor and not overlapping with the lateral incisor root is called sector I (a). Sector II (b) is the area in which the canine crown and lateral incisor root appear overlapped and sector III (c) is the area in which the canine crown appears to have passed through the lateral incisor.



**Figure 3** The bicondylar line (Warford *et al.*, 2003), the standard line in evaluating the impacted canine angulation, is created by joining the most superior point on both condyles.

classified as ‘severe resorption with pulp involvement (S)’. Using these three categories, the degree of root resorption was evaluated with images from all three planes—sagittal, coronal, and horizontal—of a CT image.

To measure the intra-examiner agreement for radiographic image assessment, 30 subjects were selected randomly for re-evaluation. The kappa test result for this data ( $\kappa = 0.892$ ) showed high intra-examiner agreement.

#### Statistical analysis

Data were analysed by employing the SPSS Windows version 12.0 software (SPSS Inc., Chicago, Illinois, USA). The dependent variable (degree of root resorption) was qualitative and classified into three categories, with values in ascending order. Therefore, the ordinal logistic regression analysis model was used. The significance of the statistical comparison between the impacted angulation of the canine and the impacted position were tested using the independent

two-sample *t*-test for the buccopalatal position and the one-way analysis of variance test for the mesiodistal position. Also, a chi-square test was performed to detect the difference in mesiodistal placement according to the buccopalatal position of the impacted canine. The level of statistical significance was set at 5 per cent.

#### Results

The age of the subjects was distributed between the ages of 8–19 years, with the majority of the subjects being 9–14 years. Of these subjects, 59 were male (70 teeth) and 89 were female (116 teeth), with a 50 per cent greater prevalence in females. Of the 186 teeth from the subjects, 95 were right canines and 91 were left canines that showed no particular difference.

It is evident from the distribution of the impacted canine position (Table 1) that there are 140 buccally impacted canines to 46 palatally impacted canines, which is a 3-fold greater prevalence for the buccal side. The rate percentage of root resorption turned out to be as high as 49.5 per cent ( $R = 32.8$  per cent,  $P = 16.7$  per cent).

The factors affecting adjacent root resorption were analysed using ordinal logistic regression analysis (Table 2). Firstly, the gender ( $P = 0.554$ ) and the left and right position of the canines ( $P = 0.854$ ) were of no influence to adjacent root resorption. However, the buccopalatal position ( $P < 0.0001$ ) of impacted canines is a significant influential factor for adjacent root resorption. Also, a coefficient value that is larger than 0 shows that there is a tendency for a buccally impacted canine to resorb the root to a greater degree than a palatally impacted canine. Sectors II ( $P = 0.037$ ) and III ( $P = 0.006$ ) were statistically significant, such that mesiodistal placement is also an influential factor for adjacent root resorption. The coefficient values of both sectors II and III were also larger than 0, which demonstrates a tendency for more severe root resorption for teeth in sectors II and III than teeth in sector I.

As a result of analysing the variations in impacted angulation according to the position of the impacted canine (Table 3), all *P*-values were greater than 0.05. Hence, there is no statistical difference in impacted angulation depending on the position of the tooth.

#### Discussion

Besides third molars, the impaction of maxillary canines is the most common eruption disturbance in permanent dentition (Ericson and Kurol, 1986; Andreasen *et al.*, 1997). There has been a long history of research on this subject. Through this research, the general tendencies of maxillary canine impaction have been repeatedly proven by many researchers. The most representative tendency would be a prevalence for impaction that is greater in females and greater on the palatal side.

**Table 1** The distribution of the impacted canine position. BP, buccopalatal; MD, mesiodistal.

	MD placement			Total
	Sector I	Sector II	Sector III	
BP position				
Buccal	30	40	70	140
Palatal	2	12	32	46
Total	32	52	102	186

**Table 2** Results of ordinal logistic regression analysis about adjacent root resorptions. BP, buccopalatal; CI, confidence interval; MD, mesiodistal; OR, odds ratio.

	P	OR	95% CI
Impacted angulation	0.652	1.003	0.987–1.021
Gender			
Male	0.554	1.215	0.638–2.315
Female		1	
Upper right canine	0.854	0.944	0.512–1.739
Upper left canine		1	
BP position			
Buccal	<0.0001	4.041	1.951–8.369
Palatal		1	
MD placement			
Sector III	0.006	19.472	2.320–163.441
Sector II	0.037	10.003	1.153–86.755
Sector I		1	

**Table 3** The statistical comparison between the impacted position and its angulation. The significance was tested using the independent two-sample *t*-test for the buccopalatal position and the one-way analysis of variance for the mesiodistal placement.

	Mean $\pm$ SD	P
BP position		
Buccal	54.15 $\pm$ 18.84	0.255
Palatal	50.46 $\pm$ 17.89	
MD placement		
Sector I	50.68 $\pm$ 18.58	0.063
Sector II	58.09 $\pm$ 16.25	
Sector III	52.11 $\pm$ 26.15	

This study also supports the consensus of a greater prevalence in females than males. In terms of buccopalatal positioning, this study displays an opposing opinion that there is a 3-fold greater tendency for buccal impaction. Taking the findings from this study into account, there is now proof that there was a greater tendency for impaction on the buccal side in the Korean population. Then, why is it that Koreans display an opposing tendency to that of the

previous studies? The author thinks that the main reason is the difference in jaw bone structure for different races. According to the report by [Zhong et al. \(2006\)](#), the Chinese also displayed a greater prevalence of buccal impactions by 2.1 times, a similar tendency to the findings from our study. This report by Zhong strongly supports our opinion since the previous studies were mostly performed in Europe and America with Caucasians being the subject race. The influential factors for such differences are regarded as factors associated with the shape of the maxilla and those that can vary the position of the tooth germ, such as the maxillary arch form, height of the palatal vault, and width of the nasal cavity. In accordance to this subject, further research must be performed.

[Ericson and Kurol \(2000\)](#) had reported the percentage of adjacent root resorption of ectopically erupting maxillary canines as 48 per cent using the CT images. Our study also had a similar value (49.5 per cent). Like these results showed, more root resorption can be detected using CT images because these images provide information in three different planes. No matter how excellent the periapical radiographic images may be, these images only show lateral and apical resorptions due to the limited projection angle. Therefore, buccal and palatal resorptions cannot be detected from these images. The evaluation of adjacent root resorption can be more precise using CT images.

Previous studies were mostly focused on the prevalence. This study focused on finding the properties of impacted canines, which affect root resorption. As seen in Table 2, the gender and distinction between right and left tooth positioning showed no difference. It can be predicted that a complication-like root resorption is caused by localized factors. Therefore, as a result of evaluating localized factors, such as impacted angulation, buccopalatal position, and mesiodistal placement, the two positioning aspects revealed a significant influence on root resorption. Thus, there is a greater possibility of root resorption when the impacted canine is placed buccally and a greater tendency to resorb the root more severely when it is placed mesially, overlapping with the lateral incisor.

So far, the pathogenesis of the root resorption is unclear and a complex biological process that is not well understood ([Alqerban et al., 2009](#)). However, this results support the suggestion that physical force of the impacted canine plays an important part in root resorption ([Ericson et al., 2002](#)). Ericson's research suggested that the dental follicle could resorb the periodontal contour but cannot directly resorb the hard tissue of the root. Ericson also stated that the majority of the action upon root resorption is from physical contact, active pressure, and the cellular activities of a contact point between the canine crown and adjacent root. It can easily be predicted that there would be a greater possibility of physical contact between the canine crown and lateral

incisor root when they appear more overlapped. Also, considering the position of the lateral incisor root in the alveolar bone housing, it is apparent that there is a larger area of cancellous bone towards the palatal side of the lateral incisor root than between the buccal cortical bone and root. Therefore, when the impacted canine is positioned buccally, the impacted tooth seems to apply a greater force on the lateral incisor root than when it is placed palatally, due to the insufficient space. Because Koreans showed a 3-fold greater prevalence of impaction on the buccal side, there was also an increased number of cases with poor prognosis. Thus, for dentists treating the Far East Asian patients, it is important to periodically check panoramic radiographic images for buccal impactions, and when a tendency for maxillary canine impaction is found, cautious follow-up is necessary.

It was stated that the angulation of the maxillary canine showed no significant difference in the presence of impaction (Wardford *et al.*, 2003). Our study also found no significant relationship between the presence of root resorption and impacted angulation. Therefore, it is irrational to predict the possibility of adjacent root resorption purely by looking at impacted angulation.

## Conclusions

This study began with the intention of investigating the different clinical aspects of maxillary canine impaction in a Korean population compared to that of a Caucasian population. As a result, the following conclusions can be made:

1. The maxillary canine impaction in the Korean population occurred more frequently on the buccal side than the palatal side by a 3-fold margin and more frequently in females than in males by a 1.5-fold margin.
2. Tooth resorption in the CT images showed a large percentage value of 49.5 per cent.
3. More severe root resorption was apparent when the impacted canine was positioned buccally and when the canine crown overlapped the lateral incisor root by a greater area.
4. The impacted angulation evident in the panoramic radiographic image did not have any statistically significant relations with either the impacted position or the root resorption.

## References

- Alqerban A, Jacobs B, Willems G 2009 Root resorption of the maxillary lateral incisor caused by impacted canine: a literature review. *Clinical Oral Investigations* 13: 247–255
- Andreasen J O, Petersen J K, Laskin D M 1997 Textbook and color atlas of tooth impactions, 1st edn. Munksguard, Copenhagen
- Becker A 2007 The orthodontic treatment of impacted teeth, 2nd edn. Informa Healthcare, London
- Becker A, Smith P, Behar R 1981 The incidence of anomalous maxillary lateral incisors in relation to palatally-displaced cuspids. *Angle Orthodontist* 51: 24–29
- Dachi S F, Howell F V 1961 A survey of 3,874 routine full mouth radiographs. *Oral Surgery, Oral Medicine, and Oral Pathology* 14: 1165–1169
- Ericson S, Bjerklin K, Falahat B 2002 Does the canine dental follicle cause resorption of permanent incisor roots? A computed tomographic study of erupting maxillary canines. *Angle Orthodontist* 72: 95–104
- Ericson S, Kurol J 1986 Radiographic assessment of maxillary canine eruption in children with clinical signs of eruption disturbances. *European Journal of Orthodontics* 8: 133–140
- Ericson S, Kurol J 1987 Radiographic examination of ectopically erupting maxillary canines. *American Journal of Orthodontics and Dentofacial Orthopedics* 91: 483–492
- Ericson S, Kurol J 2000 Incisor root resorptions due to ectopic maxillary canines imaged by computerized tomography: a comparative study in extracted teeth. *Angle Orthodontist* 70: 276–283
- Fournier A, Turcotte J, Bernard C 1982 Orthodontic considerations in the treatment of maxillary impacted canines. *American Journal of Orthodontics* 81: 236–239
- Jacoby H 1983 The etiology of maxillary canine impaction. *American Journal of Orthodontics* 84: 125–132
- Kung S H, Hwang C J 1993 Diagnosis and treatment plan of maxillary impacted canine. *Korean Journal of Orthodontics* 23: 165–177
- Lindauer S J, Rubenstein L K, Hang W M, Anderson W C, Isaacson R J 1992 Canine impaction identified early with panoramic radiographs. *Journal of American Dental Association* 123: 91–97
- Mevlut C, Hasan K, Husamettin O 2010 Investigation of transmigrated and impacted maxillary and mandibular canine teeth in an orthodontic patient population. *Journal of Oral Maxillofacial Surgery* 68: 1001–1006
- Oliver R G, Mannion J E, Robinson J M 1989 Morphology of the maxillary lateral incisor in cases of unilateral impaction of the maxillary canine. *British Journal of Orthodontics* 16: 9–16
- Rui H, Liang K, Kaijin H 2010 Investigation of impacted permanent teeth except the third molar in Chinese patients through an x-ray study. *Journal of Oral Maxillofacial Surgery* 68: 762–767
- Stellzig A, Basdra E K, Kourposch G 1994 The etiology of canine tooth impaction: a space analysis. *Fortschritte der Kieferorthopädie* 55: 97–103
- Thilander B, Myrberg N 1973 The prevalence of malocclusion in Swedish school children. *Scandinavian Journal of Dental Research* 81: 12–20
- Warford J H Jr, Grandhi R K, Tira D E 2003 Prediction of maxillary canine impaction using sectors and angular measurement. *American Journal of Orthodontics and Dentofacial Orthopedics* 124: 651–655
- Zhong Y L, Zeng X L, Chen L 2006 Clinical investigation of impacted maxillary canine. *Zhonghua Kou Qing Yi Xue Za Zhi* 41: 483–485